

---

# THE ADVENT OF THE ENDOSCOPE IN TRANSSPHEOIDAL SURGERY

**ENRICO DE DIVITIIS, MD, PAOLO CAPPABIANCA, MD,  
LUIGI MARIA CAVALLO, MD, DOMENICO SOLARI**

*Department of Neurological Sciences - Unit of Neurosurgery  
Università degli Studi di Napoli Federico II,  
Naples, Italy*

---

Transsphenoidal surgery performed with the aid of an endoscope has rapidly developed in recent years and many centers are now performing "pure" or endoscope-assisted transsphenoidal approaches.

An overview of the role of the endoscope in pituitary surgery, from the first attempts to the current techniques is presented.

## **HISTORICAL OVERVIEW**

Neuroendoscopy was born in 1910 with Victor Darwin Lespinnasse, urologist from Chicago, who performed the first ventricular endoscopy and coagulation of the choroid plexus for treatment of hydrocephalus [9]. Only after more than 50 years the endoscope was employed in transsphenoidal surgery.

Guiot was the first in 1963 to suggest the use of the endoscope within the transnasorhinoseptal transsphenoidal approach, to make an exploration of the sellar content [14], thus starting the experience of endoscope assisted microneurosurgery in the transsphenoidal route. Apuzzo [1] in the 1970s captured this concept, adding a dimension of safety and precision to the procedure, but these experiences remained almost isolated for many years.

In the 90's a significant contribution to the use of the endoscope in transsphenoidal surgery has been made by otolaryngologists [13, 15, 23-25]. The widespread use of the endoscope in paranasal sinus surgery, thanks to the FESS (Functional Endoscopic Sinus Surgery) [19, 20, 22, 27], which represents the standard modern approach to the sinonasal pathology, has re-opened the eyes of neurosurgeons on the possibility to employ the endoscope in transsphenoidal surgery.

During the same time period technical advances, particularly the development of the computer chip TV video camera in 1986 [28], the so-called CCD camera ("charged coupled device"), the improvement of illumination with the xenon cold light sources, the miniaturization and the better quality of vision of the endoscopes and many other devices employed in each kind of endoscopic procedure, contributed to the explosion of endoscopy, also in transsphenoidal surgery.

Starting from the begin of the 90's, many different techniques have been employed in the endoscopic approach to the pituitary: endonasal, transnasal, via one or two nostrils, with or without the transsphenoidal retractor, but the last refinement, standardized in clinical practice, must be ascribed to Hae Dong Jho [16] and was followed by our group [2, 10]. It consists of an endoscopic endonasal unilateral approach, performed via an anterior sphenoidotomy, without the use of a transsphenoidal speculum, with a rigid diagnostic endoscope as the sole visualizing instrument, and no post-operative nasal packing.

## **THE PRESENT**

The endoscopic transsphenoidal approach has the same indications as the conventional microsurgical technique [10, 16], and has enjoyed progressive acceptance among surgeons and patients in the last decade, for its minimal invasiveness and for the excellent surgical view it provides [2, 7, 10-12, 16-18]. It requires specific endoscopic skills, and is based on a rather different concept, since the endoscopic view that the surgeon receives on

the video monitor is not the transposition of the real image, as it would be looking through the eye-piece of a microscope, but it is the result of a microprocessor's elaboration.

As for all endoscopic procedures, it is mandatory that all the surgical tools and instruments are the best available, because they all are part of a "clock mechanism", where the single cog-wheel if not working inexorably biases the final results.

That means the final quality of the whole procedure is related to the weaker element of that mechanism. This assumption explains why, in our Institution, even at the beginning of our experience, our attention focused on the research and the development of a new surgical dedicated instrumentation [3].

The standard procedure is nowadays carried out in several centers all over the world: it is performed without the nasal speculum, through only one nostril, with one or two instruments introduced into the nasal cavity and then into the sphenoid sinus, with the endoscope acting as a guide. In the following paragraph the surgical procedure

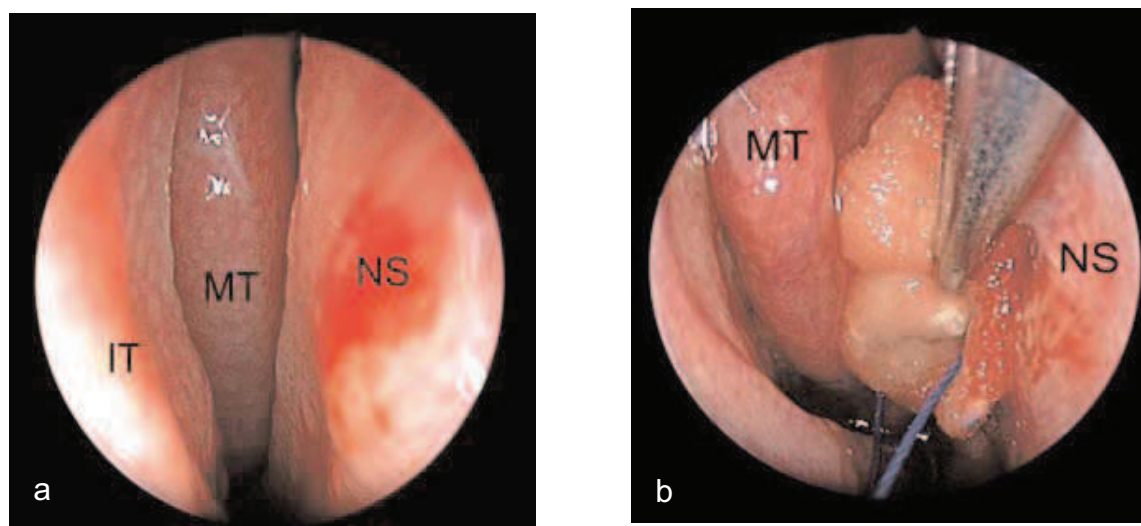
currently performed in our Institute is described.

#### THE "PURE" ENDOSCOPIC ENDONASAL TRANSSPHENOIDAL APPROACH.

The procedure, we employed since 1997 on more than 300 patients, is commonly performed through one nostril, without the nasal speculum, using the endoscope as the only tool to visualize the surgical field and with one or two instruments inserted in the same nostril close to the endoscope, gliding along it.

The patient is positionated in a so called "cradle like" position, i.e. supine with the trunk tilted 10 degree and the head turned 10 degree toward the surgeon and fixed in a Mayfield headrest without pins, and the legs slightly elevated.

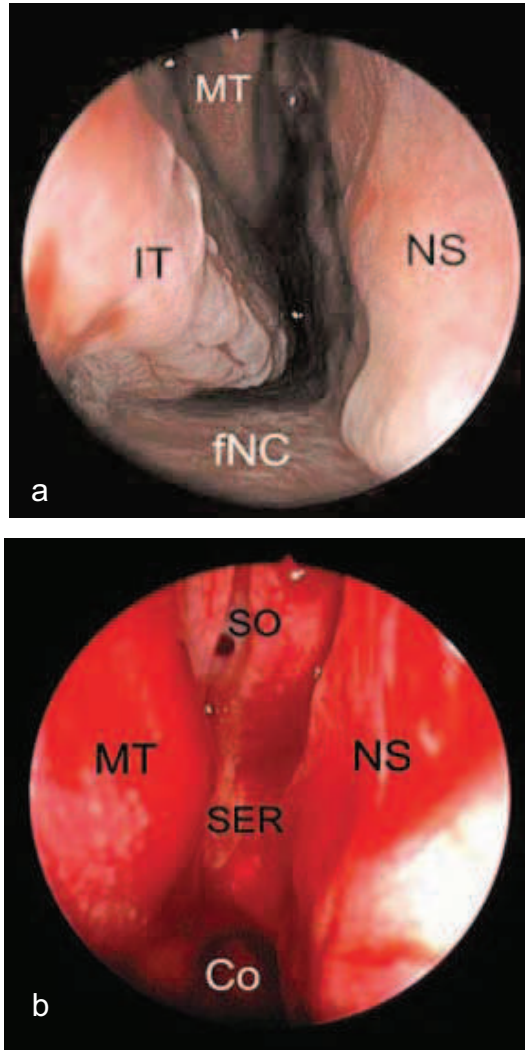
After an adequate application in both nasal cavities of cottonoids soaked in decongestant solution, the rigid endoscope (18 in length, 4 mm in diameter) is inserted in the chosen nostril up to the middle turbinate, that is gently pushed laterally to enlarge the space between it and the nasal septum (Fig.1).



**Fig.1 : Right nostril approach.**  
Nasal phase of the procedure.

- a: Identification of the middle turbinate and of the nasal septum.
- b: Positioning of a cottonoid between the middle turbinate and the nasal septum and lateralization of the head of the middle turbinate with an elevator. NS: nasal septum; IT: inferior turbinate; MT: middle turbinate.

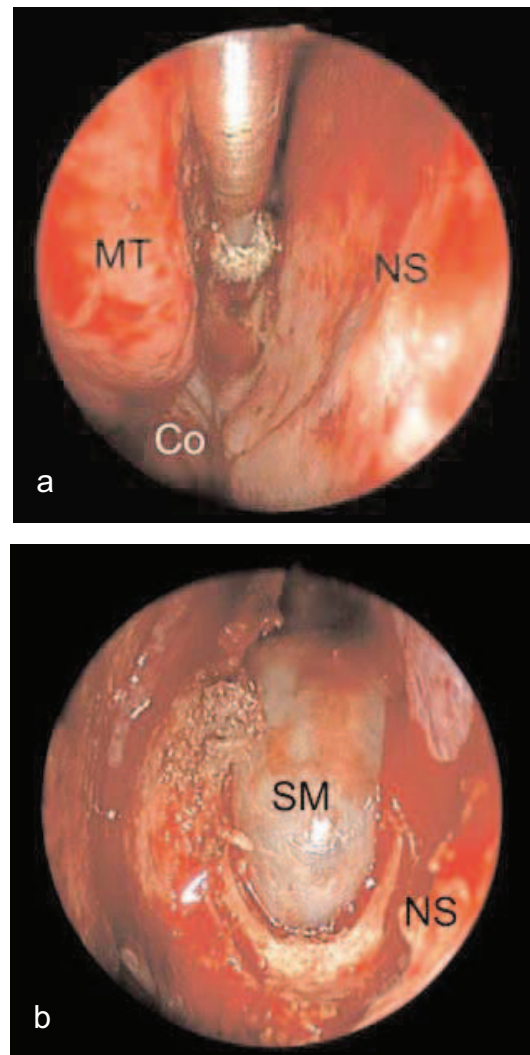
The endoscope is advanced along the floor of the nasal cavity, between the inferior turbinate and the nasal septum, up to the choana; angling then the endoscope along the roof of the choana, in the sphenomethmoid recess for about 1,5 cm, the natural sphenoid ostium is reached (Fig. 2)



**FIG 2:** Right nostril approach.  
Nasal phase of the procedure.

- a : Identification of the landmarks along the floor of the nasal cavity.
- b : Exploration of the posterior part of the nasal cavity after the lateralization of the middle turbinate. fNC: floor of the nasal cavity; NS: nasal septum; IT: inferior turbinate ; MT : middle turbinate; Co: choana ; SER: sphenomethmoid recess; SO: sphenoid ostium.

and then enlarged all around, mainly in medial direction in order to join the contralateral ostium (Fig.3).

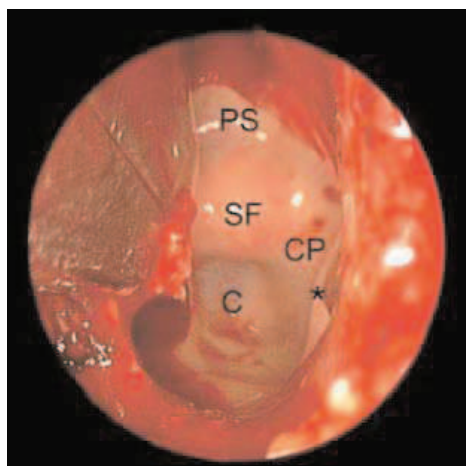


**FIG 3:** Right nostril approach.  
Sphenoid phase of the procedure.

- a: Detachment of the nasal septum from the sphenoid rostrum by means of a microdrill with diamond burr.
- b) Exposure of the sphenoid mucosa. NS: nasal septum; MT: middle turbinate; Co: choana; SM: sphenoid mucosa.

The sphenoid rostrum is removed and an anterior sphenoidotomy is then completed (Fig. 4).

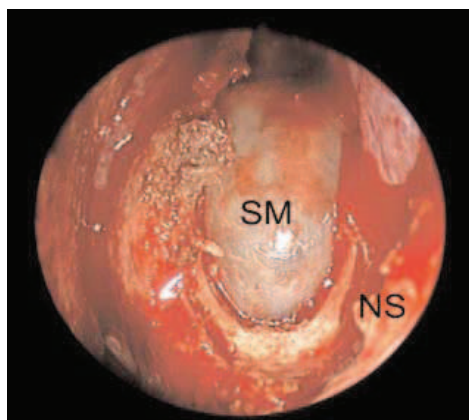




**FIG 4 :** Right nostril approach Sphenoid phase of the procedure. Enlargement of the anterior sphenoidotomy with bone punches. SF: sellar floor; CP: carotid protuberance; C: clivus; PS: planum sphenoidale; \*: sphenoid septum.

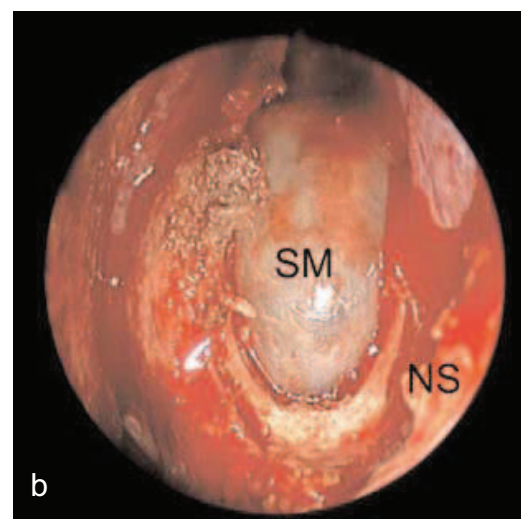
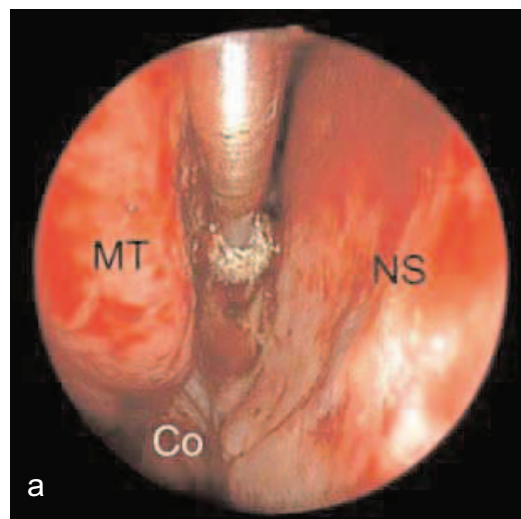
A longer endoscope (30 in length, 4 mm in diameter), from the sphenoidotomy to the removal of the lesion, is fixed to an autostatic holder and the proper instruments are inserted through the same nostril, parallel to the endoscope. Inside the sphenoid sinus one or more septum/a are removed, as needed.

On the posterior wall of the sphenoid cavity the sellar floor is recognizable, with the speno-ethmoid planum above it and the clival indentation below; lateral to the sella the bony prominences of the intracavernous artery and the optic nerve can be seen and between them the opto-carotid recess (Fig. 5).



**FIG 5:** Right nostril approach. Sphenoid phase of the procedure. Identification of the landmarks inside the sphenoid sinus. SF : sellar floor ; CP : carotid protuberance ; C: clivus ; PS : planum sphenoidale OP : optic protuberance ; OCR : opto-carotid recess ; \*: sphenoid septum.

In the next steps the sellar floor is opened, the dura madre is incised in a linear or cross fashion and an initial removal of the lesion is then performed (Fig.6).



**FIG 6 :** Right nostril approach. Sellar phase of the procedure.  
a) Removal of the lesion with a ring curette (intra-suprasellar craniopharyngioma).  
b) View after the removal of the lesion. DM: dura mater; SF: sellar floor.

After the removal of the intrasellar portion of the lesion the sellar cavity is explored with 0° or angled (30°, 45°) endoscopes, to remove the residual tumor tissue or to check an eventual source of CSF from the suprasellar cistern. At the end of the procedure the sellar floor is closed by means of a dural substitute and fibrin glue [5], if necessary, according to the common sellar reconstruction techniques [6, 26].

In our experience, the residual space in the sellar cavity after removal of the lesion can be left free, in selected cases, without any increased risk of post-operative complications. Only in about 1/3 of patients, sellar reconstruction is necessary. Lumbar drainage is adopted in case of intraoperative CSF leaks, only when the closure is not judged absolutely watertight, or when minimal unexpected post-operative CSF leakage occurs.

Some advantages, pitfalls and peculiar aspects related to this technique must be highlighted:

- The main advantages of the endoscopic procedure, as compared to the microsurgical approach, are related to the properties of the endoscope itself and to the absence of the nasal speculum [11]. Avoiding the use of the nasal speculum, which creates a "fixed tunnel" and an almost coaxial restriction of the microinstruments, the endoscope discloses its superior properties, permitting a wider vision of the surgical field, with a close-up "look" inside the anatomy. The angled lens endoscopes enable the surgeon to work on tumors located in supra and parasellar regions under direct visual control.

- There is no nasal mucosal disruption and great respect for the inner nose. The beginning of the true operation takes place with the enlargement of the sphenoid ostium and the inspection of the sphenoid sinus.

- In almost all cases no nasal packing is employed and post-operative breathing difficulties are reduced.

- The use of an endoscopic approach is particularly advantageous in case of recurrent or residual tumors already treated with a transsphenoidal operation, [4] where the sphenoid sinus is already enlarged by the former approach, thus rendering the procedure straightforward, as compared to the microsurgical transsphenoidal method.

- The wide anatomic view of the surgical field the endoscope offers minimizes the chance of a misdirected orientation, thus reducing the possibility of injury to the intra and parasellar structures and the overall percentage of surgical complications [8].

- Concerning the disadvantages of the endoscopic approach, the standardization of the endoscopic technique requires a steep learning curve to become confident with the unfamiliar anatomy of the nasal cavities and with the specific endoscopic dexterity. Nevertheless, after adequate experience, the operating time becomes the same or shorter than that required for transsphenoidal microsurgery, especially in case of recurrences.

- The endoscope offers only a bi-dimensional vision on the video monitor, without the sense of deepness, even if the latter can be gained, with the surgeon's experience, making the endoscope execute in and out movements, looking for many anatomical landmarks ; moreover the endoscope lens produces images with maximal magnification at its center and contraction at its periphery (barrel effect), and the nearest images are disproportionately enlarged while remote images are falsely miniaturized (this effect is minimal with the new scopes).

- Dedicated microsurgical endoscopic instruments with secure grip, not bayonet shaped, provided with different and variably angled tips are useful to reach the surgical targets, particularly those that the angled endoscopes are able to show.

## THE FUTURE

Despite recent preliminary reports of initial series of pure endoscopic transsphenoidal surgery [7, 17, 21], conclusive results from this new procedure in terms of completeness of lesion removal, recurrence rate and endocrine cure are not yet available, delaying a truly objective judgement.

The endoscope, in a well pneumatised sphenoid sinus, has opened the eyes of the surgeon upon structures like the planum sphenoidale, the clivus, the carotid and optic bony protuberances, from upside down the common surgical view.

Therefore pathologies arising or extending in these regions seem candidate to be removed through the transsphenoidal approach, such as craniopharyngiomas, tuberculum sellae meningiomas,

macroadenomas involving the cavernous sinus, upper clival chordomas.

The next steps of the evolution of endoscopic transsphenoidal surgery are linked to ongoing work utilizing intraoperative magnetic resonance imaging and robotics, which already exist in some advanced units, to the miniaturization of the optical systems in terms of "chip-stick technology" (i.e. miniaturized computer-based cameras held in the operating area by thin supports), to the cooperation between different technologies and industries.

### REFERENCES

- [1] APUZZO MLJ, HEIFETZ M, WEISS MH, KURZE T: Neurosurgical endoscopy using the side-viewing telescope. Technical note. *J Neurosurg* 16 : 398-400, 1977.
- [2] CAPPABIANCA P, ALFIERI A, DE DIVITIIS E: Endoscopic endonasal transsphenoidal approach to the sella: towards Functional Endoscopic Pituitary Surgery (FEPS). *Minim Invasive Neurosurg* 41: 66-73, 1998.
- [3] CAPPABIANCA P, ALFIERI A, THERMES S, BUONAMASSA S, DE DIVITIIS E : Instruments for endoscopic endonasal transsphenoidal surgery. *Neurosurgery* 45 : 392-396, 1999.
- [4] CAPPABIANCA P, ALFIERI A, COLAO A, CAVALLO LM, FUSCO M, PECA C, LOMBARDI G, DE DIVITIIS E : Endoscopic endonasal transsphenoidal surgery in recurrent and residual pituitary adenomas. Technical note. *Minim Invasive Neurosurg* 43 : 38-43, 2000.
- [5] CAPPABIANCA P, CAVALLO LM, MARINIELLO G, DE DIVITIIS O, BECERRA ROMERO ADC, DE DIVITIIS E : Easy sellar reconstruction in endoscopic transsphenoidal surgery with polyester-silicone dural substitute and fibrin glue : technical note. *Neurosurgery* 49: 473-476, 2001.
- [6] CAPPABIANCA P, CAVALLO LM, ESPOSITO F, VALENTE V, DE DIVITIIS E : Sellar repair in endoscopic endonasal transsphenoidal surgery : results of 170 cases. *Neurosurgery* 51: 1365-1372, 2002.
- [7] CAPPABIANCA P, CAVALLO LM, COLAO A, DEL BASSO DE CARO M, ESPOSITO F, CIRILLO S, LOMBARDI G, DE DIVITIIS E: Endoscopic endonasal transsphenoidal approach : outcome analysis of 100 consecutive procedures. *Minim Invas Neurosurg* 45: 1-8, 2002.
- [8] CAPPABIANCA P, CAVALLO LM, COLAO A, DE DIVITIIS E: Surgical complications of the endoscopic endonasal transsphenoidal approach for pituitary adenomas. *J Neurosurg* 97: 293 - 298, 2002.
- [9] DAVIS L : *Neurological Surgery*. Philadelphia, Lea & Febiger, 1939, pp 405.
- [10] DE DIVITIIS E, CAPPABIANCA P: Endoscopic endonasal transsphenoidal surgery. *Adv Tech Stand Neurosurg* 27 : 137-177, 2002.
- [11] DE DIVITIIS E, CAPPABIANCA P, CAVALLO LM: Endoscopic transsphenoidal approach: adaptability of the procedure to different sella lesions. *Neurosurgery* 51 : 699-707, 2002.
- [12] DE DIVITIIS E, CAPPABIANCA P, CAVALLO LM: Endoscopic endonasal transsphenoidal approach to the sellar region. In de Divitiis E, Cappabianca P (eds) : *Endoscopic Endonasal Transsphenoidal Surgery*. Wien New York, Springer, 2003, pp. 91-130.
- [13] GAMEA A, FATHI M, EL-GUINDI A: The use of the rigid endoscope in transsphenoidal surgery. *J Laryngol Otol* 108: 19-22, 1994.
- [14] GUIOT G, ROUGERIE J, FOURESTIER M, FOURNIER A, COMOY C, VOULMIERE J, GROUX R: *Explorations endoscopiques intracrâniennes*. Press Med 71 : 1225-1228, 1963.

- 
- [15] JANKOWSKI R, AUQUE J, SIMON C, MARCHAL JC, HEPNER H, WAYOFF M : Endoscopic pituitary tumor surgery. *Laryngoscope* 102: 198-202, 1992.
- [16] JHO HD, CARRAU RL, KO Y : Endoscopic pituitary surgery, in Wilkins RH, Rengachary SS: *Neurosurgical Operative Atlas*. American Association of Neurological Surgeons, Park Ridge, Ill. 5, 1996, pp 1-12.
- [17] JHO HD, CARRAI RL: Endoscopic endonasal transsphenoidal surgery: experience with 50 patients. *J Neurosurg* 87: 44-51, 1997.
- [18] JHO HD: Endoscopic transsphenoidal surgery. In Schmidek HH (ed): *Schmidek & Sweet Operative Neurosurgical Techniques*. Philadelphia, W.B. Saunders, 2000, 1, pp. 385-397.
- [19] KENNEDY DW: Functional Endoscopic Sinus Surgery. Technique. *Arch Otolaryngol* 111: 643-649, 1985.
- [20] MESSERKLINGER W: Background and evolution of endoscopic sinus surgery. *Ear Nose Throat J* 73: 449-450, 1994.
- [21] NASSERI SS, KASPERBAUER JL, STOME SE, MCCAFFREY TV, ATKINSON JL, MEYER FB: Endoscopic transnasal pituitary surgery: report on 180 cases. *Am J Rhinol* 15: 281-287, 2001.
- [22] SENIOR BA, KENNEDY DW, TANABODEE J, KROGER H, HASSAB M, LANZA D: Long-term results of functional endoscopic sinus surgery. *Laryngoscope* 108: 151-157, 1998.
- [23] SETHI DS, PILLAY PK : Endoscopic management of lesions of the sella turcica. *J Laryngol Otol* 109: 956-962, 1995.
- [24] SETHI DS, PILLAY PK: Endoscopic surgery for pituitary tumors. *Op Tech Otolaryngol Head Neck Surg* 7: 264-268, 1996.
- [25] SHIKANI AH, KELLY JH: Endoscopic debulking of a pituitary tumor. *Am J Otolaryngol* 14: 254-256, 1993.
- [26] SPAZIANTE R, DE DIVITIIS E, CAPPABIANCA P: Repair of the sella after transsphenoidal surgery, in Schmidek HH, Sweet WH (eds): *Operative Neurosurgical Techniques. Indications, Methods and Results*: Philadelphia, W.B. Saunders Company, 2000, 1, pp 398-416.
- [27] STAMMBERGER H, POSAWETZ W: Functional Endoscopic Sinus Surgery. Concepts, indications and results of the Messerklinger technique. *Eur Arch Otorhinolaryngol* 247: 63-76, 1990.
- [28] STELLATO TA: History of laparoscopic surgery. *Surg Clin North Am* 72: 997-1002, 1992.